

TOSHIBA

Leading Innovation >>>



Ultrasound-guided breast-conserving surgery to improve surgical accuracy

Nicole M. A. Krekel, Sybren Meijer, Petrousjka M.P. van den Tol,
Department of Surgical Oncology, VU University Medical Centre, Amsterdam, the Netherlands

Viamo
performance to go

Introduction

Breast-conserving surgery for breast cancer has been developed to accomplish two major goals: the achievement of tumor-free resection margins and prevention of local recurrence, and improved cosmetic outcome with conservation of normal adjacent breast tissue. The literature reports poor cosmetic outcomes in 20–40% of patients after breast-conserving surgery, with the volume of the resected breast tissue being the major determinant specifically when the excision volume exceeds 85 cm³. Surgical resection of palpable breast cancer is performed with guidance by intra-operative palpation. These palpation-guided excisions often result in an unnecessarily wide resection of adjacent healthy breast tissue, while the rate of tumor-involved resection margins is still high (Fig. 1). Since there is clear evidence for the efficacy of ultrasonography in the resection of non-palpable tumors it is hypothesized that the use of intra-operative ultrasonography in the excision of palpable breast cancers will improve the ability to spare healthy breast tissue while maintaining or even improving the oncological margin status and providing potentially better cosmetic and quality of life outcomes.

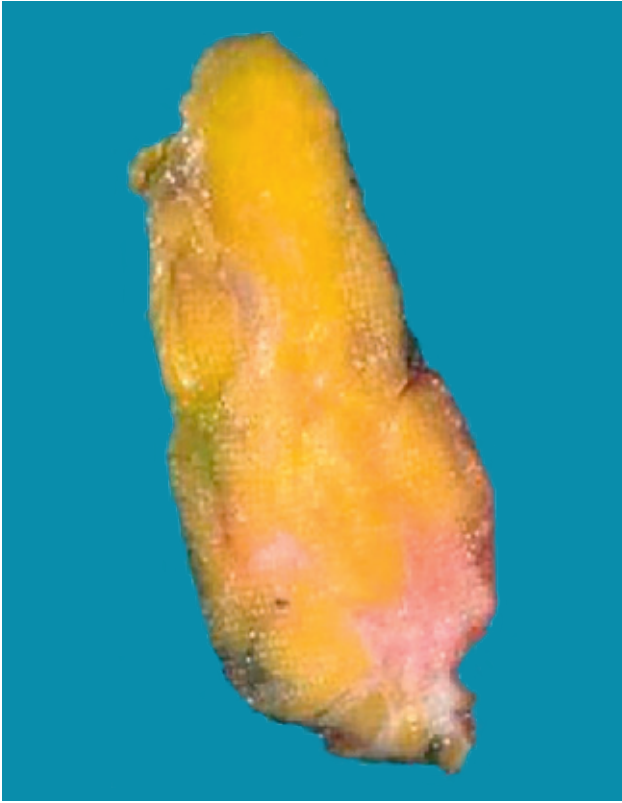

Fig. 1: Specimen with eccentric tumor localization.

In a prospective randomized controlled multicentre trial ultrasound-guided surgery for palpable tumors will be compared with the standard palpation-guided surgery in terms of the extent of healthy breast tissue resection, the percentage of tumor-free margins, cosmetic outcomes and quality of life. Presented here are some preliminary findings and an outline of the objectives of this study.

Study methods

Full ethical approval was obtained for this study from the Investigational Review Board of the VU University Medical Centre, the detailed procedural method can be reviewed in the publication by Krekel et al (BMC Surgery 2011, 11:8 <http://www.biomedcentral.com/1471-2482/11/8>).

Briefly, between October 2010 and December 2011, 120 women diagnosed with palpable early-stage (T1-2N0-1) primary invasive breast cancer and deemed suitable for breast-conserving surgery were randomized between ultrasound-guided surgery and palpation-guided surgery. The main objective being to obtain adequate resection margins with optimal resection volumes. Experimental design and sample numbers were designed to achieve an expected 20% reduction of resected breast tissue and an 18% difference in tumor-free margins by the adoption of ultrasound guidance during surgical excision. These quantitative variables as well as cosmetic outcomes and quality of life will be evaluated post surgery.

Ultrasound-guided procedure

For the ultrasound-guided surgery, breast surgeons target and excise the tumors, assisted by ultrasound imaging. The surgeons carefully localize the breast tumor and obtain surgically relevant measurements. Tumor diameter (transverse versus vertical), the lesion-to-skin distance and the lesion-to-fascia distance are measured in millimeters, allowing the tumor margins to be precisely marked on the skin (Fig. 2 & 3). After making the incision, the extent of dissection is determined using the skin marks and additional ultrasound imaging, which further assists the surgeons with the excision. To achieve adequate margins, ultrasound is applied repeatedly in or around the wound from different angles while continuously monitoring the location and depth of the tumor and ensuring the maintenance of adequate resection margins. Finally, a spherical lump of breast tissue is excised (Fig. 4). After excision, the specimen is examined with ultrasound ex vivo to determine whether the tumor is completely excised (Fig. 5). If the margin appears inadequate, additional breast parenchyma can be excised at that site. In the ultrasound guided surgical group, tumor excision was performed by the surgeon with ultrasound guidance in collaboration with an experienced radiologist. The study was conducted with Toshiba's Viamo portable ultrasound system. This system provided the high degree of mobility required in this study design, allowing for easy positioning in the operating theatre and also for transportation between the participating clinical centers. Additionally, the Viamo combines this mobility with ease of use and high level image quality, making it the ideal imaging tool for this study.

Initial training phase

During the initial training phase three individual surgeons each performed 10 ultrasound-guided excisions. All tumors were correctly identified during surgery, 29 of 30 tumors (96.7%) were removed with adequately negative margins; and one tumor was removed with focally positive margins. Over the training period, resection volumes markedly improved and reached optimal volumes.

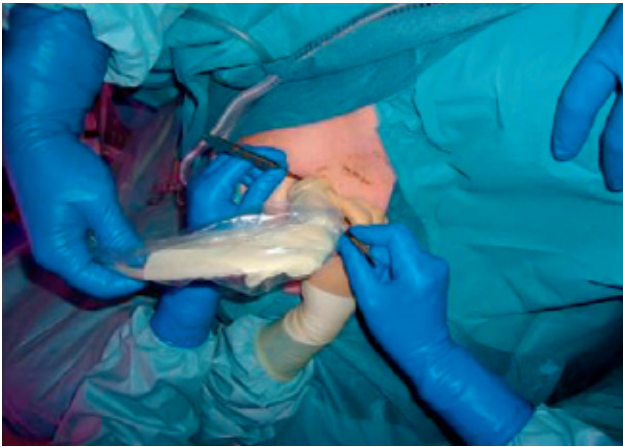


Fig. 2: Tumor localization by means of ultrasound imaging.

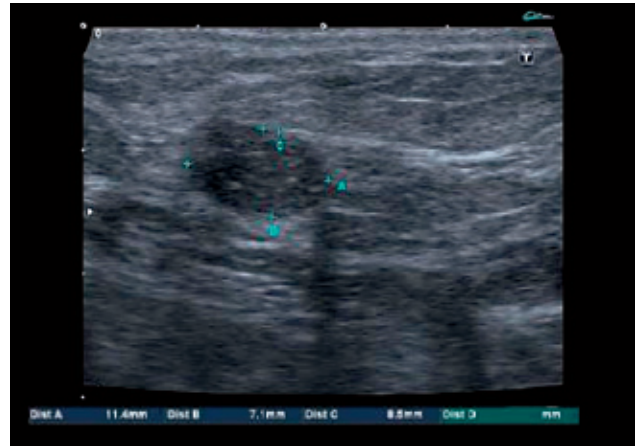


Fig. 3: Ultrasound image on screen.

By the 8th procedure, all surgeons showed proficiency in performing intraoperative breast ultrasound imaging. It can be concluded that surgeons can easily learn the skills needed to perform intraoperative ultrasonography for palpable breast tumor excision. The technique is non-invasive, simple, safe and effective for obtaining adequate resection margins and optimal volumes, thereby, presumably better achieving the goals and expectations of breast conserving surgery together with improved cosmetic outcomes.

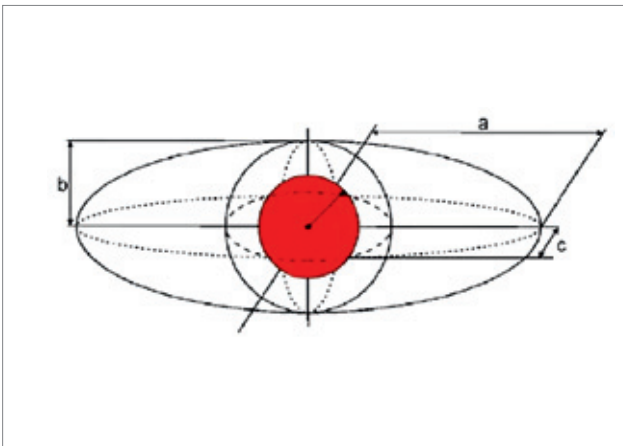


Fig. 4: Comparing the specimen volume with the optimal excision volume.

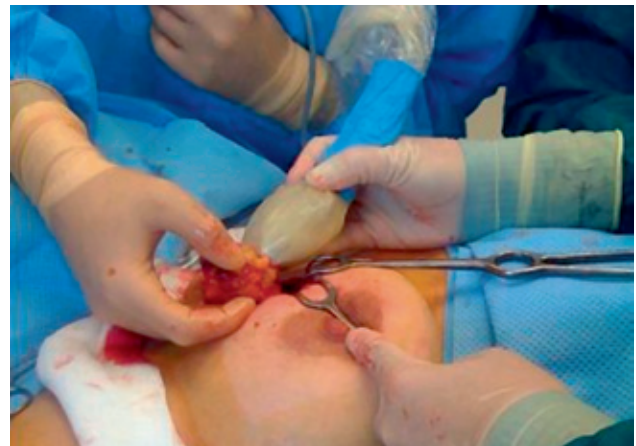

Fig. 5: Ultrasound is applied repeatedly in the wound.

Conclusion

The use of intra-operative ultrasonography in the excision of palpable breast cancers will probably improve the ability to spare healthy breast tissue while maintaining or even improving the oncological margin status. In a prospective, multicentre, randomized controlled study the efficacy of ultrasound-guided breast-conserving surgery in patients with palpable early-stage primary invasive breast cancer in terms of the sparing of breast tissue, oncological margin status, cosmetic outcomes and quality of life are under investigation. Preliminary findings suggest that the Viamo is ideal for such imaging and that surgeons can acquire the necessary intraoperative imaging skills quickly. The data will provide evidence in the near future as to the benefits of this new ultrasound application.

References

Krekel et al. BMC Surgery 2011,11:8
<http://www.biomedcentral.com/1471-2482/11/8>

TOSHIBA MEDICAL SYSTEMS CORPORATION

©Toshiba Medical Systems Corporation 2012 all rights reserved.
Design and specifications subject to change without notice.
06/2012 MCSUL0015EUC
Printed in Europe

www.toshiba-medical.eu



ULTRASOUND CT MRI X-RAY SERVICES